

CLINICAL RESULTS WITH A POSTERIOR CHAMBER IOL



Outcomes were good, but return trips to the OR were required for some eyes.

BY SUPHI TANERI, MD, FEBOS-CR; AND CAROLINE HANSSON, MSC

To date, results with at least four models of posterior chamber phakic IOLs of different designs and materials have been discussed in the literature: the Visian ICL (STAAR Surgical),¹ the Refractive Implantable Lens (RIL, Appasamy),² the Eyecryl Phakic IOL (Biotech Vision Care),³ and the Implantable Phakic Contact Lens (IPCL, Care Group).^{4,5} In this article, we retrospectively report our results with the latest IPCL, the IPCL V2.0, in 74 myopic and myopic-astigmatic eyes treated from April 2018 to January 2020.

PERSONAL EXPERIENCE AND RESULTS

At 3 months postoperative, mean uncorrected distance visual acuity (UDVA) was 1.09 (Snellen decimal scale), mean efficacy index (mean postoperative UDVA/mean preoperative corrected distance visual acuity [CDVA]) was 1.08, and mean safety index (mean postoperative CDVA/mean preoperative CDVA) was 1.24. At 1 year after implantation, mean UDVA was 1.04, even though a toric lens had rotated in one eye.

Average endothelial cell loss between implantation and 3-month follow-up was 1.7% (Figure 1).

Mean IOP was 15.0 ± 3.1 mm Hg before implantation. All patients received oral acetazolamide after surgery, and an aqueous release to reduce IOP was performed within a few hours after surgery in six eyes. IOP spikes on the day of implantation were associated with remnants of the OVD used. No glaucoma, uveitis, or any other vision-threatening complication was observed, and at 3 months, the average IOP was lower than preoperatively.

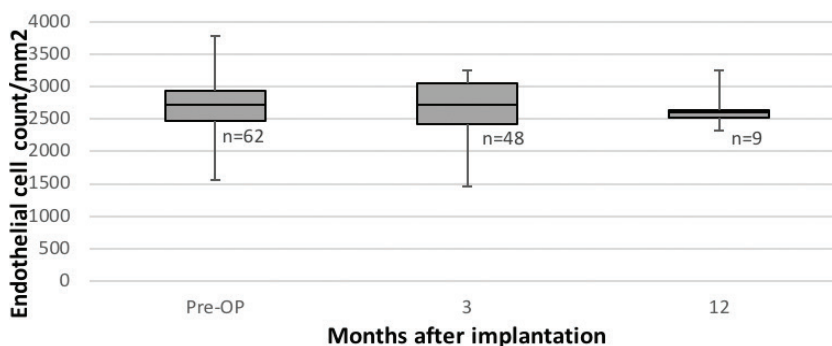


Figure 1. Endothelial cell loss after IPCL implantation over time as measured with noncontact specular microscopy (SP-3000P, Topcon).

TABLE. ADDITIONAL SURGICAL INTERVENTIONS (FIVE EYES, EIGHT PROCEDURES)

Patient 1
Revision of a rotated IPCL toric (14 days PI); second revision 1 day later (15 days PI). After 1.5 months, LASIK was performed because of repeated rotation of IOL.
Patient 2
Revision of rotated IPCL in both eyes 14 days PI. After 4 months, LASIK was performed in one eye.
Patient 3
One IPCL rotated after 12.5 months and was revised 14 months PI. Six weeks later, the lens had rotated again to the same position. Patient is still considering LASIK.
Patient 4
IPCL explanted 8 months PI because of visually significant cataract formation. This amblyopic eye had early lens opacity preoperatively, but IPCL implantation rather than refractive lens exchange was chosen to prevent anisometropia because of previous retinal detachment in the fellow eye.
Abbreviation: PI, postimplantation

We have not yet exchanged an IPCL due to sizing issues. However, additional surgical interventions were performed in five eyes (Table). In one eye (Patient 4 in Table), the toric IPCL had rotated 87° twice without any history of ocular trauma (Figure 2). Of note, the lens vault was within the acceptable range in all eyes at all visits, including the IPCLs that had rotated.

OFF-LABEL USES

We have used the IPCL off-label in nine eyes in which laser vision correction and RLE were not preferable options. In five eyes, implantation was classified as off-label because the patient was older than 45 years at the time of surgery. The other four off-label eyes were in two prepresbyopic sisters with bilateral endothelial cell counts of

(Continued on page 33)

disinfectant when patients get up (Figure 3). We have set up cleaning protocols for each exam room, and there are signs outside each room to tell us whether it is clean or needs to be cleaned. This is extremely helpful on a busy day. Each of us pitches in to make sure everything is clean and ready for the next patient.

These are unprecedented times, and each and every day we have to be ready

for changes that make us smarter and our patients and staff members safer. We need to listen to and learn from all our colleagues as we go. The situation is ever-changing, and, unfortunately, no one has all the answers. ■

P. DEE G. STEPHENSON, MD, FACS

- Founder, Stephenson Eye Associates, Venice, Florida
- Member, *CRST* Editorial Advisory Board

(Continued from page 18)

less than 2,000 cells/mm². Due to their level of accommodative capacity, a RLE was ruled out. The two patients had no signs of ocular pathologies despite very thin corneas, and we are monitoring them closely after implantation.

Recovery after surgery and results have been satisfactory in all off-label uses except for one eye in which an early lens opacity became visually disturbing, necessitating IPCL removal and cataract surgery (Patient 4 in Table).

DISCUSSION

Our initial visual and refractive outcomes and our experience with complications are comparable to our results with the Visian ICL V4c.⁶ Further, our results validate the findings of Vasavada et al, who reported low surgical and postoperative complications and good visual results at 3 years after IPCL implantation.⁵




Figure 2. Toric IPCL rotated almost 90° at 12.5 months after implantation.

We observed no need for refractive nomogram adjustment when transitioning from ICL to IPCL. However, we have performed eight additional surgical interventions after implantation; seven of those were performed because the toric IPCL rotated postoperatively. After the orientation was corrected, most of the rotated IPCLs then rotated back into the same orientation, and we finally treated these patients with LASIK.

The rotation of toric IPCLs was the most important negative issue we experienced. This cannot simply be explained by undersizing of the IPCL because postoperative vaulting was within the acceptable limits of 0.125 to 1.0 mm⁷ at all postoperative visits, even after rotation. We speculate that individual anatomic factors behind the iris that are not easy to evaluate in a clinical setting might have contributed to this phenomenon.

Endothelial cell loss is a dreaded potential complication after phakic IOL implantation. The physiologic rate of endothelial cell loss is 0.3% to 0.6% per year.^{8,9} Several studies have shown that, except for the endothelial cell loss related to surgical trauma, annual endothelial cell loss is stable and predictable in the years after implantation of the ICL.¹⁰ It remains to be determined whether this is also true after IPCL implantation. However, reports by Bianchi¹¹ and Vasavada et al,⁵ like our own short-term results, are promising. Nonetheless, lens manufacturers still recommend regular follow-up after phakic IOL implantation.

■ eyedrdee@aol.com

- Financial disclosure: Consultant (Alcon, Atia Vision, Bausch + Lomb, Bruder Healthcare, Carl Zeiss Meditec, Cassini, EyePoint Pharmaceuticals, Eyevance Pharmaceuticals, Guardian Health Sciences, Kala Pharmaceuticals, Lensar, Ocular Therapeutix, Omeros, Sun Ophthalmics); Grant support (Bausch + Lomb, Ocular Therapeutix); Lecture fees (Bausch + Lomb, Carl Zeiss Meditec, Cassini, Kala Pharmaceuticals, Lensar, Ocular Therapeutix, Omeros, Sun Ophthalmics)

The main limitation of our study is its short follow-up period, with only 13 visits at 1 year. Longer follow-up is warranted to determine the long-term stability of visual and refractive results, as well as long-term implications for IOP, endothelial cell loss, and cataract formation. ■

1. Fernández-Vega-Cueto L, Lisa C, Esteve-Taboada JJ, Montés-Micó R, Alfonso JF. Implantable collamer lens with central hole: 3-year follow-up. *Clin Ophthalmol*. 2018;12:2015-2029.
2. Pandey S, Sharma V. Commentary: Expanding indications of newer and economically viable phakic posterior chamber intraocular lens designs. *Indian J Ophthalmol*. 2019;67(7):1066-1067.
3. Yaşa D, Ürdem U, Ağca A, et al. Early results with a new posterior chamber phakic intraocular lens in patients with high myopia. *J Ophthalmol*. 2018;2018:1329874.
4. Sachdev G, Ramamurthy D. Long-term safety of posterior chamber implantable phakic contact lens for the correction of myopia. *Clin Ophthalmol*. 2019;13:137-142.
5. Vasavada V, Srivastava S, Vasavada SA, Sudhakar A, Vasavada AR, Vasavada VA. Safety and efficacy of a new phakic posterior chamber IOL for correction of myopia: 3 years of follow-up. *J Refract Surg*. 2018;34(12):817-823.
6. Taneri S, Rost A, Hansson C, Kiebler S, Dick HB. Klinische Ergebnisse mit zwei phaken Hinterkammerlinsenmodellen zur Korrektur von Myopie und myopem Astigmatismus. Paper presented at: Kongress der DGfG; February 13-15, 2020; Mainz, Germany.
7. Instructions for Use. IPCL v2.0; and email communication with Tobias Otte, Polytech Domilens; 2016.
8. Cheng H, Jacobs PM, McPherson K, Noble MJ. Precision of cell density estimates and endothelial cell loss with age. *Arch Ophthalmol*. 1985;103(10):1478-1481.
9. Jorge J, Queirós A, de Matos SCP, Blasco TF, González-Mejome JM. Age-related changes of corneal endothelium in normal eyes with a non-contact specular microscope. *Journal of Emmetropia*. 2010;1(3):132-139.
10. Nakamura T, Isogai N, Kojima T, Yoshida Y, Sugiyama Y. Posterior chamber phakic intraocular lens implantation for the correction of myopia and myopic astigmatism: a retrospective 10-year follow-up study. *Am J Ophthalmol*. 2019;206:1-10.
11. Bianchi GR. Initial results from a new model of posterior chamber implantable phakic contact lens: IPCL V2.0. *Med Hypothesis Discov Innov Ophthalmol*. 2019;8(2):57-63.

SUPHI TANERI, MD, FEBOS-CR

- Director, Center for Refractive Surgery, Muenster, Germany
- Associate Professor, Ruhr-University Bochum, Germany
- Member, *CRST Europe* Editorial Advisory Board
- taneri@refraktives-zentrum.de
- Financial disclosure: Lecturer fees (Care Group)

CAROLINE HANSSON, MSC

- Optometrist, Center for Refractive Surgery, Muenster, Germany
- info@refraktives-zentrum.de
- Financial disclosure: None